
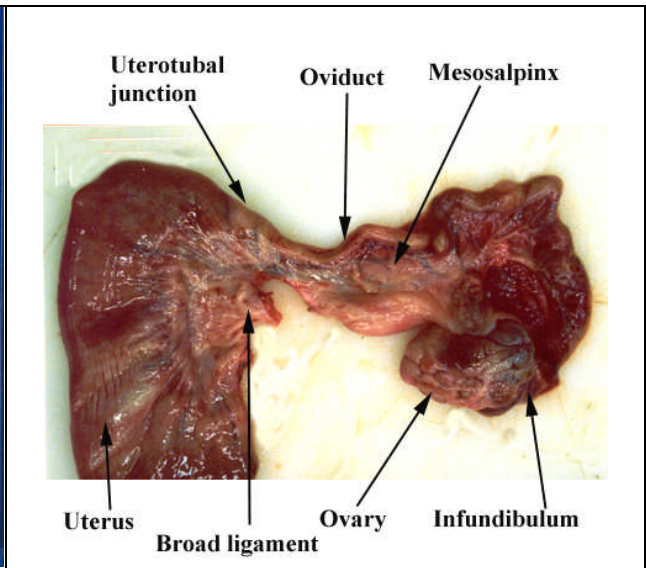





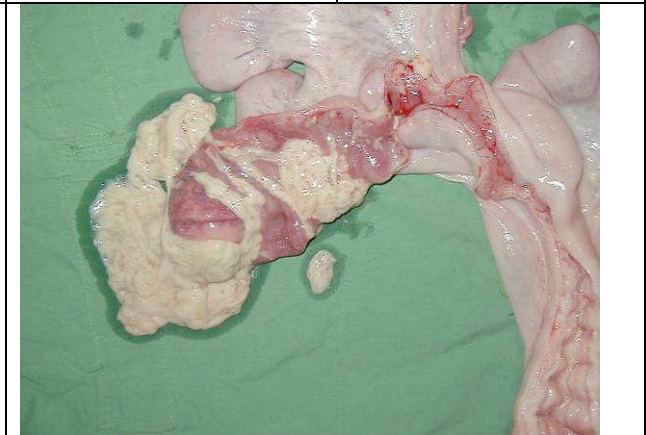


Slaughterhouse Reproductive Analysis

			
<p>Stage of pregnancy</p>	<p>Oviduct anatomy and patency</p>		
			
<p>Anoestrus</p>	<p>Follicles</p>	<p>Corpora haemorrhagica</p>	<p>Corpora lutea</p>
			
<p>Cystic changes to the ovaries and oviduct</p>	<p>Endometritis and metritis of the uterus</p>		